

NEW BEAUTY

THE BEAUTY AUTHORITY

SUMMER-FALL 2018

Elle
MACPHERSON
at 54

THE
MIDWINTER
IS
GIVE

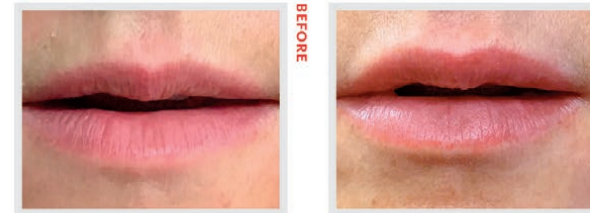HOLLYWOOD'S FAVORITE
**SECRET
SURGERY**

RADIANT *skin* **SHINY** *hair*

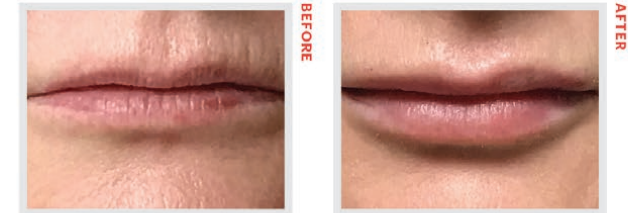INSIDE:

+ The Newest Lunchtime Laser
Head-to-Toe Vampire Facials
Summer's Best New Serums
Amazing Makeovers

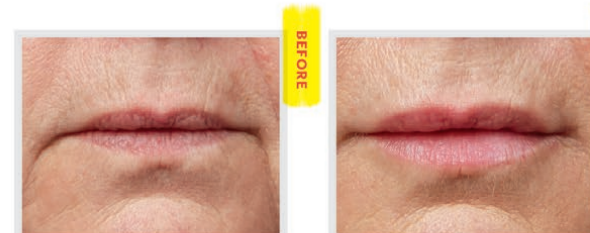THE CLINIC
GALLERY



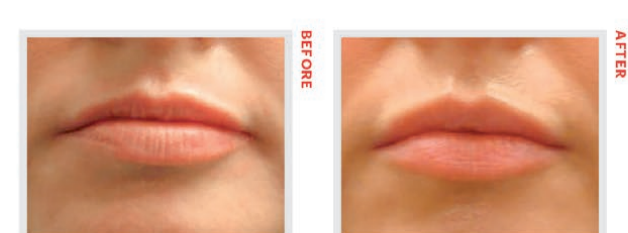
To give this 38-year-old patient the slight increase in fullness she desired, New York dermatologist Hooman Khorasani, MD injected Juvéderm Volbella in both the upper and lower lips.



Amherst, NY plastic surgeon Samuel Shatkin Jr., MD injected this 61-year-old patient's upper and lower lips with Juvéderm Ultra Plus to create a youthful-looking shape and bring balance to her face.

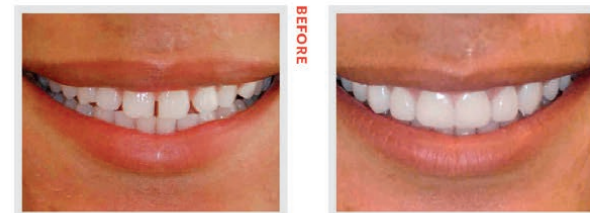

This 65-year-old patient wanted her lips to have a more youthful look. Fresno, CA dermatologist Kathleen Behr, MD used Juvéderm Vollure, off-label, to give her plumper, more voluminous-looking lips.

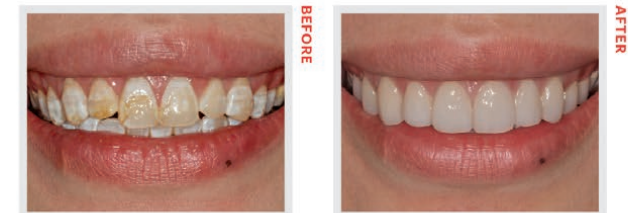

New Orleans dermatologist Deirdre Hooper, MD used Restylane Silk in this 46-year-old patient's upper and lower lips to give her the more prominent pout she desired.

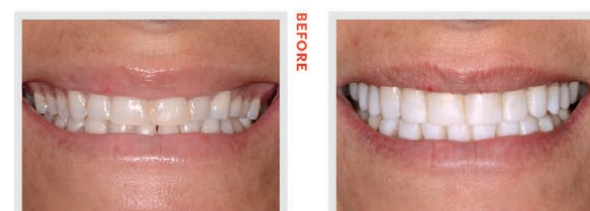SMILE MAKEOVER



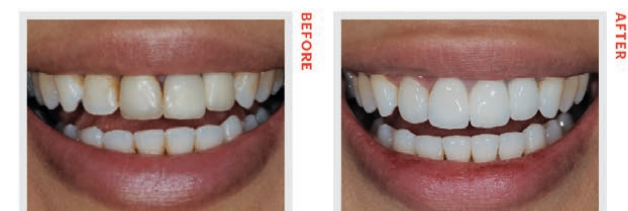This 23-year-old patient wanted to correct the spacing between her teeth and get a whiter smile. Beverly Hills, CA cosmetic dentist Kourosh Maddahi, DDS used 20 porcelain veneers for her smile makeover.



Possible excessive fluoride use left this 38-year-old patient with stained enamel, which New York cosmetic dentists Jan Linhart, DDS and Zachary Linhart, DDS corrected using porcelain veneers and gum recontouring.



To give this 34-year-old patient the brighter, more even-looking smile she desired without drilling down her teeth, New York cosmetic dentist Irene Grafman, DDS performed a smile makeover using dental bonding.



This 27-year-old patient sought Atlanta cosmetic dentist Ronald Goldstein, DDS to replace existing crowns and whiten teeth that were left with residual bonding material after the removal of orthodontic brackets.